


PATIENT

Zeus Gutierrez

PRESENTING CLINICAL SIGNS

History: Intermittent increased RR and wobbling.

SPECIES

Canine

BREED

Husky

SEX

Male

AGE

1 year

WEIGHT

40 lbs

INTERPRETED BY

 Maggie Machen Lamy,
 DVM, DACVIM
 (Cardiology)

IMAGING PERFORMED BY
HOLTER MONITOR FINDINGS AND RHYTHM ASSESSMENT

Time analyzed	23:50h
Mean heart rate	94bpm
Maximum heart rate	225bpm
Minimum heart rate	45bpm
VPCs	1
APCs	0

Interpretation: Normal sinus rhythm with apparently appropriate heart rate variability (diary not included). No prolonged pauses are noted. Occasional brief sinus pauses with bradycardia (presumably sleeping) and a single blocked p wave; however, this is a normal finding in young athletic dogs. Sinus tachycardia noted however presumably this is during activity. A single VPC is noted during a period of sinus tachycardia.

Rhythm diagnosis: Normal sinus rhythm with apparently appropriate heart rate variability. Occasional sinus pauses with 2nd degree AV block while sleeping. Single VPC.

INTERPRETATION OF THE FINDINGS & FURTHER RECOMMENDATIONS

Apparently normal recording. No significant pauses are noted, and no malignant arrhythmias identified. It is always difficult without a corresponding holter diary describing the patient's activity to know if the HR is appropriate; however, based upon time of day this is assumed. The max HR appears sinus, and likely occurs with activity. In contrast, brief pauses while sleeping is often normal in healthy dogs, with occasional blocked p waves. A single VPC is largely normal, and occurs with period of excitement.

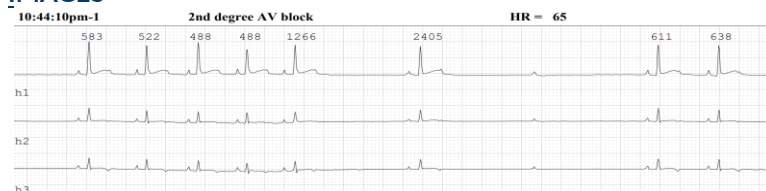
No cause for reported symptoms is seen or expected based upon these findings. CXR are strongly recommended, with an echocardiogram to follow if any cardiomegaly is appreciated.

No medications are indicated at this time.

Recheck as dictated by the clinical picture.

HOSPITAL NAME

Rockaway AH

IMAGES


AV block with sleep

REFERRING VET

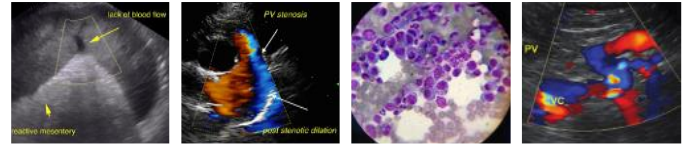
Dr. Kahn

INVOICE

28833

DATE

2/6/23



PATIENT

Zeus Gutierrez

SPECIES

Canine

BREED

Husky

SEX

Male

AGE

1 year

WEIGHT

40 lbs

INTERPRETED BY

Maggie Machen Lamy,
DVM, DACVIM
(Cardiology)

IMAGING PERFORMED BY

HOSPITAL NAME

Rockaway AH

REFERRING VET

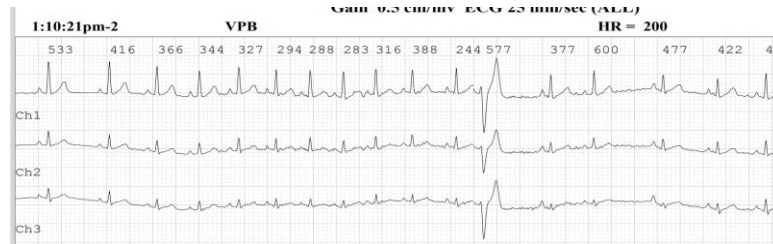Dr. Kahn

INVOICE

28833

DATE

2/6/23



Single VPC

The information and recommendations provided are based on the images presented by the referring veterinarian. No evaluation can be communicated regarding pathology that was not visible in the image/video clips provided.

Thank you for this referral. If the clinical or image interpretation does not parallel your findings or if I can be of any further assistance please contact me.

Maggie Machen Lamy, DVM
Diplomate of the American College of Veterinary Internal Medicine (Cardiology)
info@sonopath.com